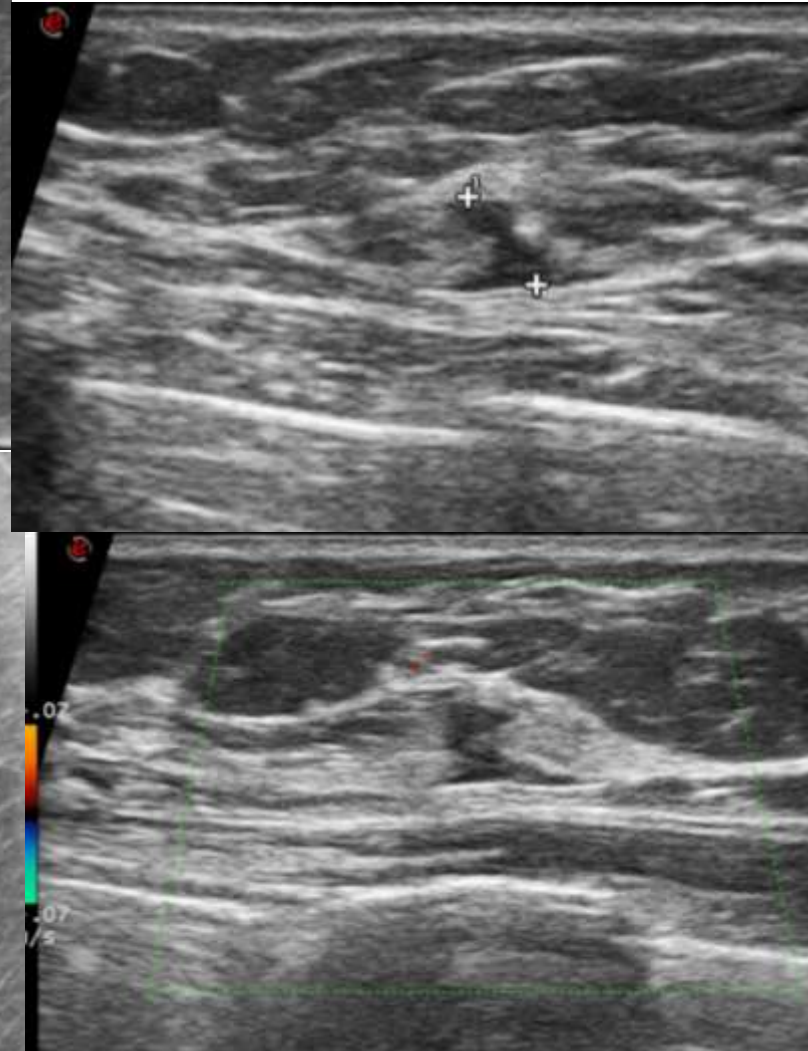
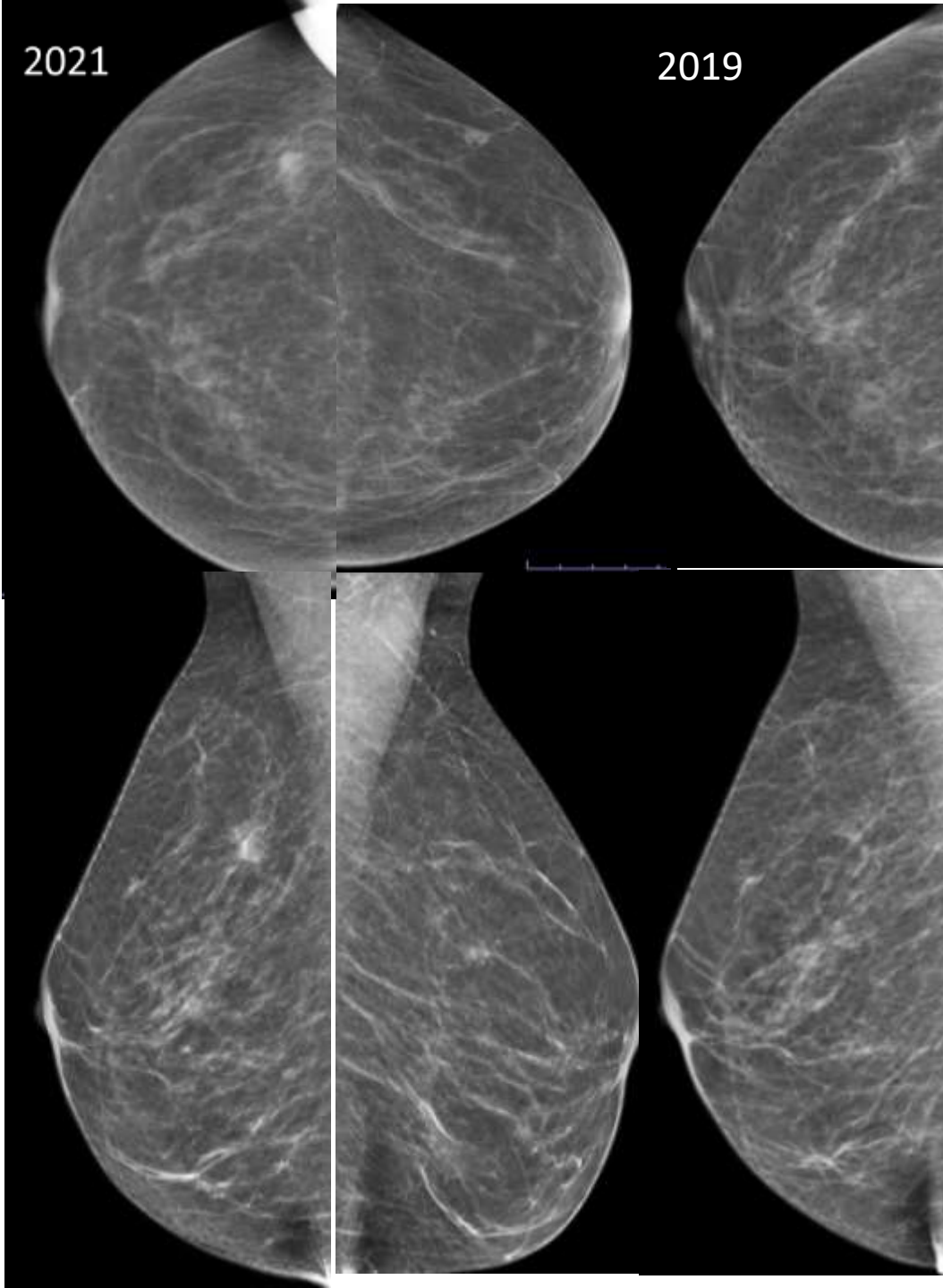


65 anni - Esame di screening
Asintomatica



Giovanni Bellini- Ritratto femminile

Prelievo microistologico sotto guida ecografica
Carcinoma duttale infiltrante di grado nucleare intermedio-alto B5b